Journal of Plastic, Reconstructive & Aesthetic Surgery (2022) 75, 2001–2018

Correspondence and Communications

A neuro-plastics approach for extracranial-to -intracranial bypass: Video and technical considerations

Dear Sir,

An extracranial-to-intracranial (EC-IC) bypass is performed to achieve cerebral revascularisation. The main indications for EC-IC bypass are: (i) flow *augmentation* such as in Moyamoya disease or in other select instances of cerebrovascular occlusive disease, and (ii) flow *replacement* such as when an intracranial artery is sacrificed in the management of complex cerebrovascular pathology or skull base tumours.[1-3] The most common of EC-IC bypass procedures involves anastomosing a branch of the superficial temporal artery (STA) to a branch of the middle cerebral artery (MCA) via a craniotomy to bypass the internal carotid artery and restore blood flow to the brain. This procedure requires neuro-microsurgical expertise. Here, we highlight the technical considerations in a joint Neuro-plastics approach for EC-IC bypass in our centre.

The surgical technique involves securing the head in a Mayfield head-clamp and exposing the affected side (See Video 1). The STA is palpated and marked out across its length; using ultrasound can be helpful for this step, in particular when marking out the STA's parietal and frontal branches (Figure 1). The calibre of the STA and its branches are assessed on pre-operative digital subtraction angiography (DSA) which is performed as part of the diagnostic work-up in all patients. An incision is made over the course of the STA and the vessel is identified just superficial to the skin and subcutaneous tissue. Careful dissection with low setting bipolar and microsurgical instruments is necessary to avoid iatrogenic injury. The choice of donor vessel from the two branches of the STA will depend on its calibre and the region of the brain targeted for reperfusion. The selected branch is dissected out as distal as possible to minimise vessel mismatch later in the procedure. We find early use of the operating microscope for dissection of the STA prevents injury and allows for more rapid dissection. Side branches are clipped with micro-ligaclips; this minimises thermal injury and vasospasm. With the dissected STA protected, the neurosurgical team then make a craniotomy exposing the target sylvian branches of the middle cerebral artery. A recipient vessel that matches the calibre of the donor vessel is selected and is carefully dissected, and we perform an end-to-end anastomosis to the STA (See Video 2, which demonstrates the anastomosis techniques). The vessels have a calibre of 1 mm, and superfine microsurgical instruments allow for an easier anastomosis. Our preferred approach is a posterior wall first anastomosis with 9/0 or 10/0 S&T. Once the clamps are released an indocyanine green (ICG) angiography is performed using the operating microscope's near-infrared camera to assess patency[4]; minor leaks are often seen. Doppler-ultrasound is also used to assess patency. If there is concern that the STA is spasmodic, papaverine is used for vasodilation. Tisseel is applied to minimise any bleeding. The bone flap is not replaced and the dura is only approximated, so as not to exert pressure on the bypass; the skin is closed in layers. An attendant consequence of not replacing the craniotomy flap is that the contiguous contact between the brain's surface and the temporalis muscle creates the possibility for extracranial-to-intracranial synangiosis, providing potential further channels for cerebral revascularisation. This concept is named "indirect revascularisation", so called because it is in contrast with the "direct"-or immediate-reperfusion delivered by EC-IC anastomosis. Due to the cerebro-occlusive nature of the underlying disease, patients are usually already on aspirin before their procedures. Aspirin is pursued throughout the peri-operative and postoperative periods. Additionally, prophylactic anticoagulation is initiated 24 h post-operatively and discontinued upon discharge. Patients are progressively mobilised from day1 post-operatively.

A total of 7 procedures were performed in a cohort of 6 patients (3 males,3 females) over the last 2 years, with a mean age of 46 years (range: 25-74years). One of the patients underwent bilateral EC-IC bypass procedure, whereby the right side was performed first followed by the left side 8 months later. The cohort's median preoperative mRankin score was 2 (range: 2-4). All patients were treated for cerebrovascular occlusive (Moyamoya and Moyamoya-like) diseases. The mean surgical time was 3 h and 28 min (range: 2 h 56 min-3 h 59 min). The frontal or parietal branch of the STA (donor vessel) was anastomosed to a frontal or temporal M4(cortical) branch of the MCA (recipient vessel). The average length of the craniotomy's greatest diameter was 37 mm (range: 21-60 mm).

Anastomosis patency was confirmed on last angiographic follow-up imaging in 4 patients, performed between 6 and 22 postoperative months. Only 1 patient demonstrated clinical worsening in the immediate post-operative period, with complete recovery noted at the 6-month clinical follow-up. 3 patients demonstrated improvement of their preoperative mRankin scores at their 6-month follow-up, 1 patient worsened clinically, and 1 patient is awaiting follow-

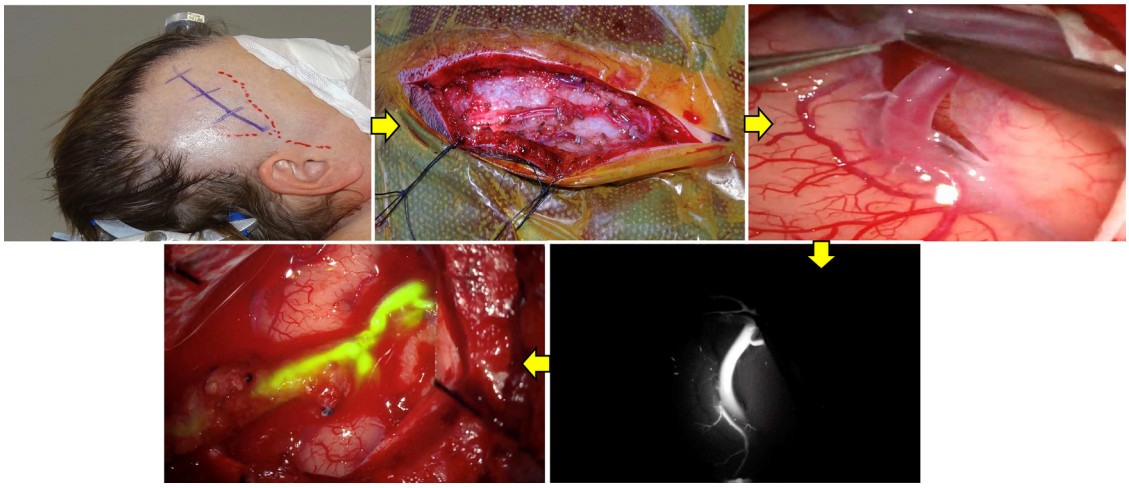

Figure 1 Technical aspects of Neuro-plastics approach for extracranial-to-intracranial bypass. Surface marking of the STA and its branches, and of incision line is shown in the first photo. Following incision, the selected branch of the STA is dissected out as distal as possible. Upon identifying the cortical recipient vessel, an M4 branch of the MCA, it is dissected and prepared. Intraoperative ICG angiography performed to assess angio-architecture of the recipient vessel. Intraoperative ICG angiography performed post anastomosis confirming flow within the bypass. STA: superficial temporal artery; MCA: middle cerebral artery; ICG: indocyanine green.

up. Post-operative perfusion imaging was performed at 6 months in 3 patients and showed improvement in all cases. 2 patients are awaiting their follow-up perfusion imaging. No delayed complications were documented in any patients.

This study highlights the unique collaboration of a plastic surgical and neurosurgical team in a microsurgical neuro-plastics approach to performing an EC-IC bypass. This multidisciplinary approach achieves favourable surgical time as well as good vascular patency.

Historically, the introduction of the surgical microscope and microsurgical technique served as a base for the subsequent development of the STA-MCA bypass procedure, with the first in-patient application of the technique having been performed by Yasargil in 1967.[3,5] EC-IC bypasses are traditionally performed by neurosurgeons, typically aided by microscope-integrated ICG angiography introduced in the mid 2000′s to intraoperatively assess bypass patency.[4] However, these procedures have become less frequent due to the narrowing of their indications.[2] The collaborative approach described here, with a mixed team of plastic surgeons who regularly perform microvascular anastomoses and of micro-neurosurgeons, may therefore facilitate EC-IC bypass procedures and enhance the surgical workflow, and so maintain favourable patient outcomes.

Financial disclosure statement

No financial disclosures to declare.

Consent

The patient has consented for use of their images and the intraoperative video.

Ethical approval

Study was conducted as a local audit hence ethical approval is not required. Study was registered with the trust as a clinical audit.

Declaration of Competing Interest

The authors have no competing interests to declare.

Acknowledgments

None.

Supplementary materials

Supplementary material associated with this article can be found, in the online version, at doi:10.1016/j.bjps.2022.02.074.

References

1. Vilela MD, Newell DW. Superficial temporal artery to middle cerebral artery bypass: past, present, and future. *Neurosurg Focus* 2008;**24**:E2.
2. Raper DMS, Rutledge WC, Winkler EA, et al. Controversies and advances in adult intracranial bypass surgery in 2020. *Oper Neurosurg* 2020;**20**:1–7 (Hagerstown).
3. Yasargil MG, Yonekawa Y. Results of microsurgical extra-intracranial arterial bypass in the treatment of cerebral ischemia. *Neurosurgery* 1977;**1**:22–4.
4. Woitzik J, Horn P, Vajkoczy P, Schmiedek P. Intraoperative control of extracranial-intracranial bypass patency by near-infrared indocyanine green videoangiography. *J Neurosurg* 2005;**102**(4):692–8 Apr.

5. Sia SF, Morgan MK. High flow extracranial-to-intracranial brain bypass surgery. *J Clin Neurosci* 2013;**20**:1-5.

Muholan Kanapathy, Dariush Nikkhah, Prateush Singh
Division of Surgery and Interventional Science, University College London, United Kingdom
Department of Plastic Surgery, Department of Plastic and Reconstructive Surgery, Royal Free NHS Foundation Trust, Royal Free Hospital, Pond Street, London NW3 2QG, United Kingdom

Joshua Solomon
Department of Plastic Surgery, Department of Plastic and Reconstructive Surgery, Royal Free NHS Foundation Trust, Royal Free Hospital, Pond Street, London NW3 2QG, United Kingdom

Afshin Mosahebi
Division of Surgery and Interventional Science, University College London, United Kingdom
Department of Plastic Surgery, Department of Plastic and Reconstructive Surgery, Royal Free NHS Foundation Trust, Royal Free Hospital, Pond Street, London NW3 2QG, United Kingdom

Mary Murphy, Ivan Cabrilo
Department of Neurosurgery, National Hospital for Neurology and Neurosurgery, Queen Square, London, United Kingdom

© 2022 British Association of Plastic, Reconstructive and Aesthetic Surgeons. Published by Elsevier Ltd. All rights reserved.

https://doi.org/10.1016/j.bjps.2022.02.074

Additional venous anastomosis in the thoracodorsal artery-based free flaps: Provision of an additional venous outflow from the thoracodorsal vein

Dear Sir,

Thoracodorsal artery-based free flaps are workhorse flaps that are widely used to reconstruct various tissue defects. The commonly used flaps include the latissimus dorsi musculocutaneous flap and thoracodorsal artery perforator flap. Anatomical studies have shown that 96% of the thoracodorsal system is composed of a single artery and vein.[1] The single venous anastomosis is often sufficient in most situations; however, when this flap is used for lower extremity reconstruction, congestion due to insufficient venous outflow may occur. Venous congestion or thrombosis has been shown to be the most common cause of flap failure and the most commonly encountered complication of free flap reconstruction in the lower extremity.[2] For this reason, it has been reported that two venous anastomoses have fewer complications than single venous anastomosis when performing free-flap reconstruction for lower extremity trauma.[2,3] Two venous anastomoses may provide sufficient outflow and contribute to a beneficial backup system if one vein becomes compromised. To date, only Goh et al. have reported the usability of the serratus anterior venous tributary as a second outflow vein in the free latissimus dorsi flaps.[1] We present an algorithm that expands on this procedure so that additional venous outflow from the thoracodorsal vein can be provided.

Before dissecting the thoracodorsal artery and vein to an appropriate length, the tributary to the serratus anterior muscle or angular vein, a tributary of the thoracodorsal vein, should be detached. One of these veins having a sufficient size should be selected and cut off at a length of approximately 1 cm. If venous congestion of the flap is suspected after anastomosis of the thoracodorsal artery and vein to the recipient artery and vein, an additional venous anastomosis should be considered. If the tributary to the serratus anterior muscle or angular vein cannot be used in a composite flap including the serratus anterior muscle and/or scapular flap, or if the vein size discrepancy between the recipient vein and the selected tributary is large, a side-to-end anastomosis with the thoracodorsal vein should be performed (Figure 1). This procedure was performed in four patients requiring reconstruction for lower extremity trauma involving open fractures as follows: end-to-end venous anastomosis with the tributary to the serratus anterior muscle ($n = 2$), end-to-end venous anastomosis with the angular vein ($n = 1$), and side-to-end anastomosis with the thoracodorsal vein ($n = 1$). The recipient veins, to which these veins were anastomosed to create an additional venous outflow, were the lesser saphenous vein ($n = 2$) and the posterior tibial vein ($n = 2$). The flap healed without any complications in all patients. Representative cases of this procedure are presented in Appendix 1.

The thoracodorsal artery is derived from the subscapular artery, which is a branch of the axillary artery. Although there are some anatomical variations, the thoracodorsal artery often gives off a branch to the serratus anterior muscle and an angular branch to the tip of the scapula during its downward course.[4] Since most veins accompany their arteries, the tributary to the serratus anterior muscle and the angular vein are easier to identify and use as additional venous outflow channels because they follow the respective arterial branches. Goh et al. reported that the tributary to the serratus anterior muscle can be cut to an avalvular segment which averages 5 mm in length.[1] Although we cut these tributaries to a length of approximately 1 cm and did not check for the presence of valves in the lumen, adequate venous drainage from these tributaries was observed. Harvesting these tributaries over long distances results in retrograde venous flow, which may disrupt adequate venous drainage. Therefore, it is advisable to keep the length of these tributaries to ≤ 1 cm, or confirm whether an avalvular segment is being used regardless of the tributary length. We performed side-to-end anastomosis with the thoracodorsal vein to create an additional venous outflow in a case where a composite flap including the serratus anterior muscle was being used; however, this is not recommended because of

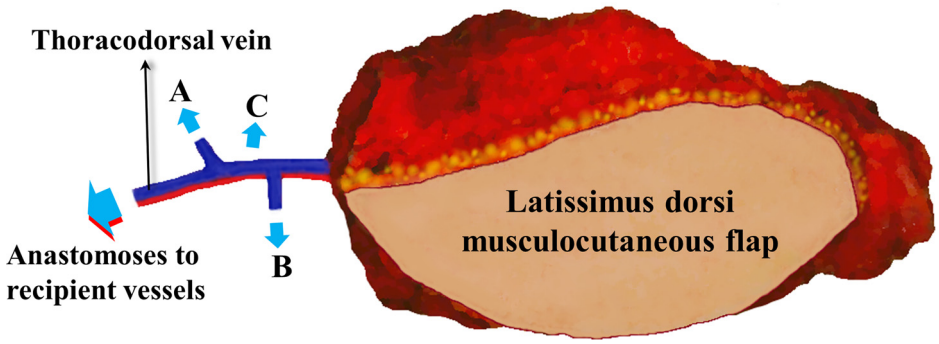

Figure 1 Schemas for creating additional venous outflow from the thoracodorsal vein. A: Tributary to the serratus anterior muscle. B: Angular vein. C: Venous outflow using side-to-end anastomosis with the thoracodorsal vein.

the complexity of the procedure. In our experience, it was easier to create venous anastomosis using the tributary to the serratus anterior muscle or the angular vein for additional venous drainage due to the simplicity of the procedure. However, since postoperative venous imaging was not performed, it remains unclear how the additional venous anastomosis contributed to improved venous outflow.

In conclusion, we believe that our technique is instrumental for preventing the failure of thoracodorsal artery-based free flaps, used for the reconstruction of the lower extremity, due to inadequate venous outflow. Further research is needed to compare our technique with conventional single venous anastomosis and to gain a better understanding of its applicability in surgical practice.

Funding

None.

Ethical approval

Not required.

Declaration of Competing Interest

The authors have no conflicts of interest to declare.

Acknowledgments

We would like to thank Editage (www.editage.com) for English language editing.

Supplementary materials

Supplementary material associated with this article can be found, in the online version, at doi:10.1016/j.bjps.2022.02.067.

Appendix 1.

Photographs of the two representative cases. Case 1 (upper left image): End-to-side anastomoses of the thoracodorsal artery and vein of the latissimus dorsi musculocutaneous flap to the posterior tibial artery and vein. Case 1 (upper right image): Additional end-to-end venous anastomosis of the lesser saphenous vein and the tributary to the serratus anterior muscle. Case 2 (lower left image): End-to-side anastomoses of the thoracodorsal artery and vein of the composite flap (latissimus dorsi musculocutaneous flap and serratus anterior muscle flap) to the posterior tibial artery and vein. Case 2 (lower right image): Additional side-to-end venous anastomosis of the thoracodorsal vein and the other posterior tibial vein.

References

1. Goh T, Tan BK, Ong YS, Chew W. Serratus anterior venous tributary as a second outflow vein in latissimus dorsi free flaps. *J Reconstr Microsurg* 2011;**27**:469–74.
2. Stranix JT, Lee ZH, Anzai L, et al. Optimizing venous outflow in reconstruction of Gustilo IIIB lower extremity traumas with soft tissue free flap coverage: are two veins better than one? *Microsurgery* 2018;**38**:745–51.
3. Shimbo K, Shinomiya R, Sunagawa T, Okuhara Y, Adachi N. Analysis of anastomotic venous factors in traumatic lower extremity injuries reconstructed by free flap. *Cureus* 2022;**14**:e20978.
4. Seneviratne S, Duong C, Taylor GI. The angular branch of the thoracodorsal artery and its blood supply to the inferior angle of the scapula: an anatomical study. *Plast Reconstr Surg* 1999;**104**:85–88.

Keisuke Shimbo, Haruka Kawamoto
Department of Plastic and Reconstructive Surgery, Hiroshima Prefectural Hospital, 5-54 Ujinakanda, Hiroshima, Japan

Isao Koshima
Department of Plastic and Reconstructive Surgery, Hiroshima University Hospital, Hiroshima, Japan
International Center for Lymphedema, Hiroshima University Hospital, Hiroshima, Japan
E-mail address: k_s08_10hyogo@hotmail.com (K. Shimbo)

© 2022 British Association of Plastic, Reconstructive and Aesthetic Surgeons. Published by Elsevier Ltd. All rights reserved.

https://doi.org/10.1016/j.bjps.2022.02.067

"Latissimus dorsi-serratus anterior tandem flap for the reconstruction of lumbosacral defects"

Dear Sir,

Lumbosacral defects present a significant challenge for reconstruction, as well-vascularized tissue of substantial bulk is limited in the region. In the scenario of spinal hardware infections or CSF leaks, reconstruction must provide soft tissue coverage and obliterate dead space, allowing the control of infection, the elimination of fluid leaks, and the salvage of hardware.

With defects of the lumbar region, latissimus dorsi and paraspinal turnover flaps can provide good coverage.[1,2] Inferiorly, defects of the lumbosacral junction are limited in treatment options. Paraspinal muscle is limited at this level with minimal mobility and bulk, while these defects are out of the reach of a latissimus dorsi flap. Coverage of lumbosacral defects require more complicated interventions, including free latissimus dorsi flaps, bipedicle latissimus dorsi with gluteus maximus muscle flaps, and reverse-supercharged latissimus dorsi flaps.[1-3]

Reverse-flow latissimus dorsi musculocutaneous flaps based on the serratus branch have been described in the context of breast reconstruction and shoulder reconstruction.[4,5] This application demonstrates the ability to use the larger latissimus dorsi muscle based on retrograde flow through the smaller seratus vessels. Similarly, the serratus anterior muscle can be carried by a reversed latissimus dorsi muscle flap, perfused by reverse flow through the thoracodorsal vessels.

We report a novel method for the reconstruction of lumbosacral defects using a latissimus dorsi-serratus anterior tandem (LST) flap based on reverse-flow through the thoracodorsal artery.

Methods

Both patients were females, 62 and 77 years old, with a history of spinal instrumentation and subsequent cerebrospinal fluid leak that failed initial paraspinal flap reconstructions at the lumbosacral junction. Due to the area of the dural repairs and previous paraspinal turnover, few local options remained. The previous adipofascial flap was viable, but likely did not have sufficient bulk to obliterate the defect. Consequently, these defects were reconstructed with LST flaps to create sufficient length to reach the defects (Figures 1and 2).

A curvilinear incision was made over the latissimus dorsi extending anteriorly to allow harvest of the serratus anterior muscle. Skin flaps were elevated off of the latissimus dorsi and serratus. The anterior border was elevated and the latissimus was dissected off of the serratus anterior. The inferior three serratus anterior slips were exposed and harvested as done for serratus anterior free flap harvest. The vascular supply of the serratus anterior was dissected to the thoracodorsal vessel junction. Dissection continued 2 cm above the junction of the serratus branch on the thoracodorsal vessels. Dissection along the superior edge of the latissimus dorsi muscle was extended with a backcut in the tendinous portion to allow for greater flap rotation (Figure 1). The serratus muscle was tunneled and inset into the defect, entirely obliterating the open area surrounding the dural repair and providing coverage of spinal hardware (Figure 2).

Figure 1 LST muscle flap following dissection. Latissimus dorsi (A). Thoracodorsal vessel (B) ligated for reverse flow to serratus anterior muscle (C).

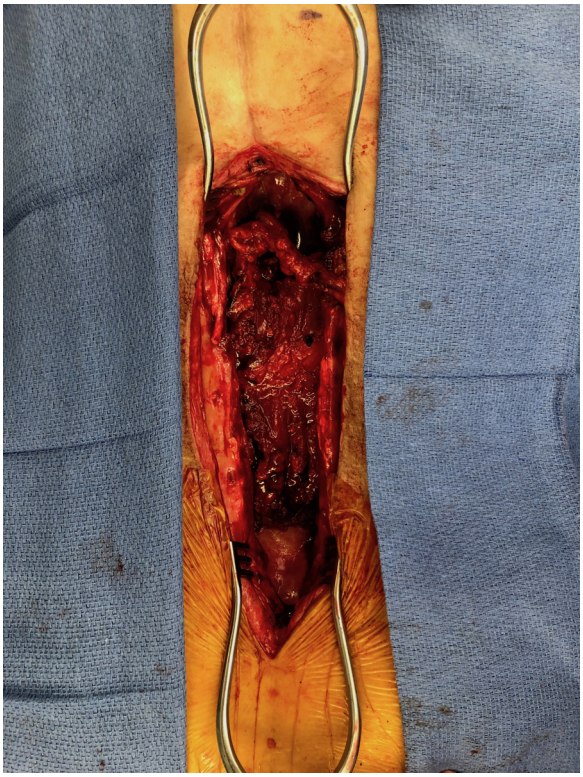

Figure 2 Lumbosacral defect obliterated with latissimus dorsi-serratus anterior turnover muscle flap.

Both patients had uncomplicated postoperative courses. Each was placed on a Clinitron air-fluidized mattress for 5 days to avoid direct pressure injury to the flaps. 1-month and 3-month follow-ups showed complete healing without evidence of recurrent CSF collection.

Discussion

This report highlights two cases of complex lumbosacral defect reconstructions by LST flap. Both cases were revision reconstructions following failed paraspinal muscle turnover flaps. Inadequate obliteration of dead space was a contributing factor to failure of previous reconstructions. Advantages of the reported method include an extended reach due to combined length of thoracodorsal and serratus vasculature, the ability to obliterate dead space with well-vascularized muscle, and no requirement for microvascular anastomosis.

The ability to reach the most inferior portions of the lumbosacral region often described as a "no-man's-land" for reconstruction is the major advantage of this approach. While latissimus turnover flaps are frequently used for lumbar defects, this workhorse flap is rarely capable of covering the lumbosacral junction with adequate bulk. Using the serratus muscle in tandem with a latissimus turnover allows for an extended vascular leash that substantially improves the flap's arc of rotation. With this method, the lumbo sacral junction can be reached without tension.

The LST flap also permits the delivery of significant, easily conformed muscle bulk to the lumbosacral region. Previously reported methods provide tissue that is less pliable and less capable of filling the entirety of the wound. While paraspinal muscle flaps provide adequate surface coverage, they do not imbricate easily into the depths of the wound, lacking sufficient bulk and failing to obliterate dead space. The LST flap requires no microanastomosis, representing a relatively easy method of transferring well-vascularized muscle bulk to the distant lumbosacral region.

Ethical approval

Not required.

Declaration of Competing Interest

None.

Funding

None.

References

1. Hochberg J, Ardenghy M, Yuen J, et al. Muscle and musculocutaneous flap coverage of exposed spinal fusion devices. *Plast Reconstr Surg* 1998;**102**(2):385–9.
2. Fontaine SD, Gaede F, Berthe JV. The reverse turnover latissimus dorsi flap for closure of midline lumbar defects. *J Plastic Reconstr Aesthetic Surg* 2008;**61**(8):917–24.
3. Hamada R, Shinaoka A, Watanabe T, Yasui H, Kimata Y. Reverse-supercharged, distally based latissimus dorsi flap for lumbar defect: a case report. *Microsurgery* 2019;**39**(5):452–6.
4. Fisher J, Bostwick J, Powell RW. Latissimus dorsi blood supply after thoracodorsal vessel division. *Plast Reconstr Surg* 1983;**72**(4):502–9.
5. Shigehara T, Tsukagoshi T, Satoh K, Tatezaki S, Ishii T. A reversed-flow latissimus dorsi musculocutaneous flap based on the serratus branch in primary shoulder reconstruction. *Plast Reconstr Surg* 1997;**99**(2):566–9.

John Vandevender
University of Illinois College of Medicine, Chicago, IL, USA

Maelee Yang, Darl Vandevender*
Division of Plastic and Reconstructive Surgery, Department of Surgery, Loyola University Medical Center, Maywood, IL, USA

*Corresponding author at: Loyola University Medical Center 2160 S First Ave, Bldg 110, Rm 3266, Maywood, IL 60153, USA.
E-mail address: dvandev@lumc.edu (D. Vandevender)

Published by Elsevier Ltd on behalf of British Association of Plastic, Reconstructive and Aesthetic Surgeons.

https://doi.org/10.1016/j.bjps.2022.02.030

The perfusion index as a noninvasive method for continuous monitoring of peripheral perfusion: A baseline study to assess the perfusion index in healthy adult volunteers

Dear Sir,

The survival of a replanted finger depends on both, the surgeon's skills and the adequate postoperative monitoring of microvascular anastomoses. The main complications are represented by arterial and venous perfusion disturbances.[1] As clinical assessment of color, turgor, temperature and capillary refill largely depends on the rater's experience, a standardized monitoring method would be of great significance for the successful monitoring of replanted fingers.[2] For this purpose, the perfusion index (PI), a parameter that is calculated from the transmission ratio between pulsatile and non-pulsatile components of the blood flow by using the photoelectric plethysmography function of a pulse oximeter, could be a useful tool. The idea was promoted in a clinical study, in which clinical monitoring of the perfusion of free flaps and replanted fingers was combined with continuous measurement of the PI.[3]

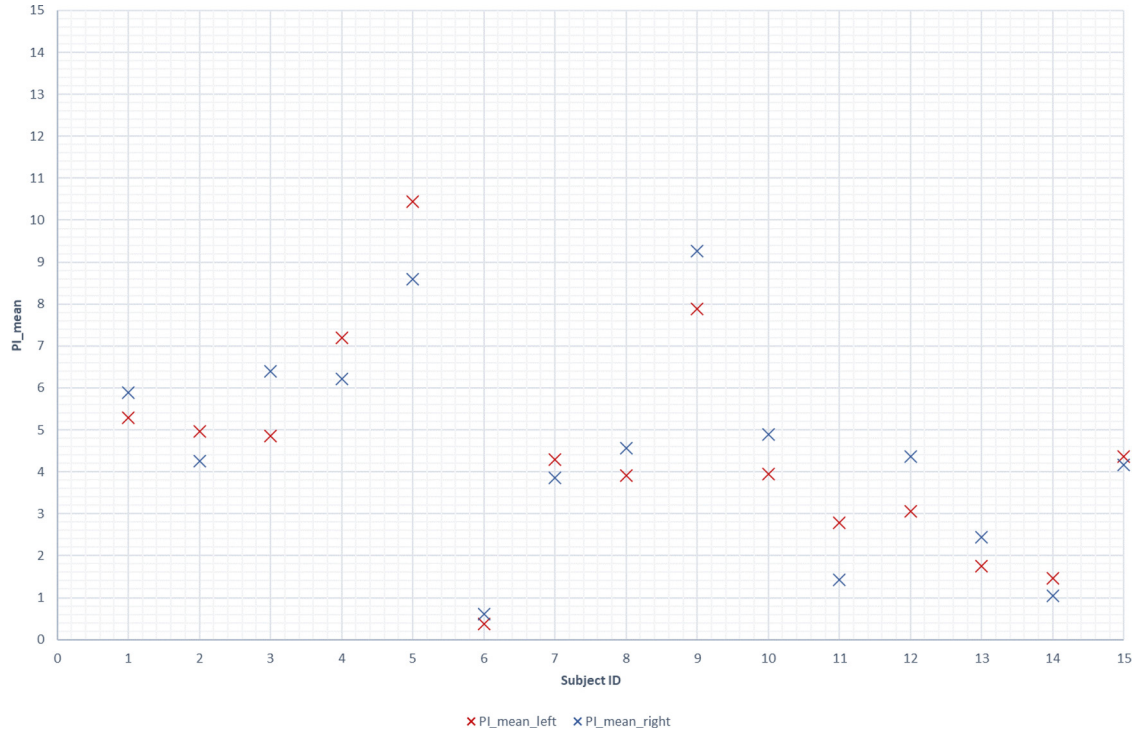

Figure 1 Graphical representation of the results of the baseline trial – Comparison of the mean values of the left and right side separately for each subject. The axis of abscissas reflects the identification number of the volunteers (a total of 15 healthy volunteers participated in this trial).
The axis of ordinates reflects the mean values of the respective perfusion indices (calculated from the transmission ratio between pulsatile and non-pulsatile components of the blood flow by using the photoelectric plethysmography function of a pulse oximeter). The values of the left sides are represented by red crosses and the values of the right sides by blue crosses. Abbreviations: ID = identification number; PI = perfusion index

The present study consists of two trials (each involving 15 subjects), which analyzes the basic characteristics of the PI in healthy volunteers to gather basic information about this parameter. Additionally, we analyze whether use of the disinfectant Braunol® (aqueous povidone-iodine solution; B. Braunol Melsungen AG, Melsungen Germany), which is regularly used in surgical disinfection, has an influence on the accuracy of the measured PI values. The disinfectant trial was inspired by the analysis of Hakverdioğlu et al. He observed that extrinsic factors, such as colored nail polish, can lead to an increased absorption of the light emitted by the pulse oximeter, which holds the potential to impact the measurement.[4]

During both trials, all subjects were placed in a seated position. Both forearms were put in front of the body on a table at heart level and palms facing down. After positioning the subjects rested for ten minutes before the measurements of 6.5 min started. The values were detected by the device Radical-7® Pulse CO-Oximeter® from Masimo (Masimo Corporation, 52 Discovery, Irvine, CA 92,618, USA) equipped with special types of finger pulse sensors (RD SET Neo Adhesive Sensor).

For the baseline trial, both index fingers were measured simultaneously in a resting state. In healthy adult subjects the PI for the left and the right hand averaged at 4.49 ± 2.70. This is in line with the results of the study by Tapar et al. in which normal values of the perfusion index were measured in various positions of the subjects.[5] In his study, PI values of 4.50 ± 2.50 were obtained for measurements in a sitting position.

In order to verify the agreement of the left and right side, a Bland-Altman-Plot (Supplemental Figure S1) was crated. The averaged difference of all values between the two sides was −0.09 ± 1.20 (SD) which is only about 2% of the average PI value and can therefore be neglected. The excellent agreement and the reliability of the comparison between the measurements of left and right sides has been confirmed by the evaluation of the interclass correlation (ICC). For the ICC a value of 0.948 (95% CI = 0.944 - 0.952) was calculated Figure 1. was created to represent the accordance of the PI values of the left and right side separately for each subject and each side. For this purpose, only the mean values without the standard deviation are shown.

For the disinfectant trial, the left index finger was disinfected with Braunol® (B. Braunol Melsungen AG, Melsungen Germany). After drying, both index fingers were measured simultaneously in a resting state. The representation of the PI values of the intervention and control side separately for each subject is shown in Figure 2. To compare the values of the different sides (finger with Braunol = intervention side; finger without Braunol = control side),

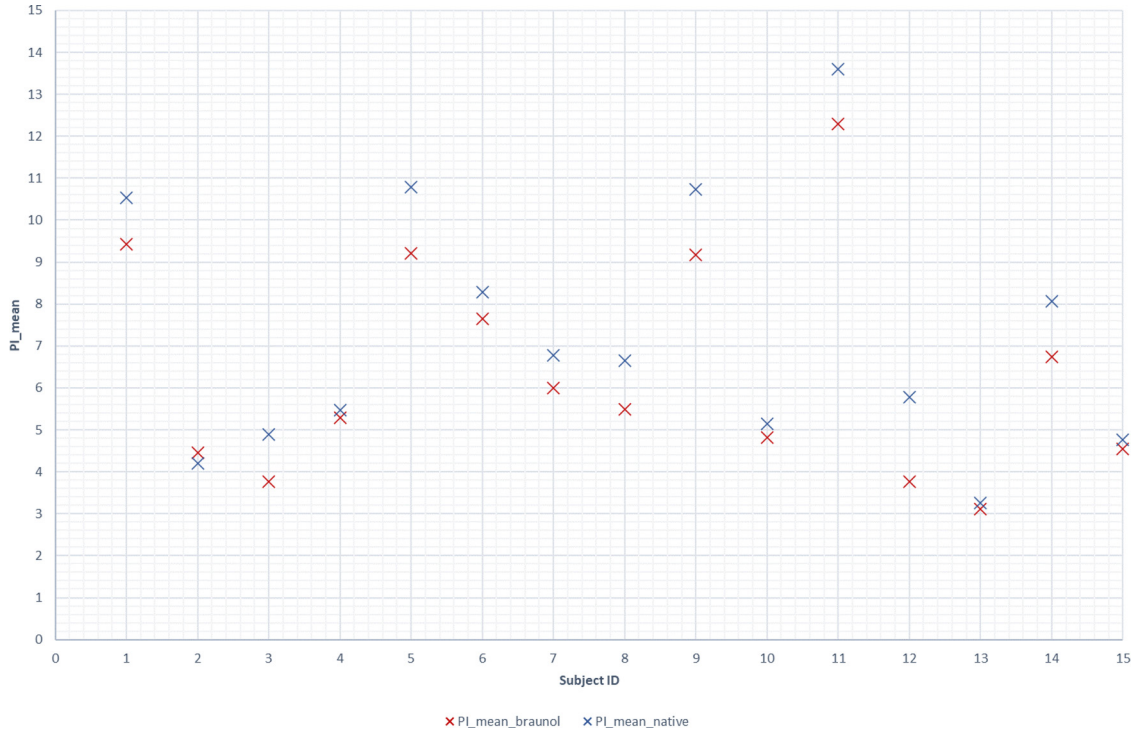

Figure 2 Graphical representation of the results of the disinfectant trial – Comparison of the mean values of the disinfectant and native side separately for each subject. The axis of abscissas reflects the identification number of the volunteers (a total of 15 healthy volunteers participated in this trial).The axis of ordinates reflects the mean values of the respective perfusion indices (calculated from the transmission ratio between pulsatile and non-pulsatile components of the blood flow by using the photoelectric plethysmography function of a pulse oximeter). The values of the braunol sides are represented by red crosses and the values of the native sides by blue crosses. Abbreviations: ID = identification number; PI = perfusion index

a paired *t*-test was performed. The intervention side revealed a smaller PI value with respect to the control side of −0.95 (95% CI = 0.91 – 0.98) in average. This difference is about ten times larger than in the baseline trial (PI = −0.09), which is statistically significant ($p < 0.001$). However, the ICC comparing PI values of the intervention side and the reference side yielded a value of 0.946 (95% CI = 0.676 – 0.979). Thus, reliability and the dynamic behavior of the two sides were almost identical to the baseline trial. This is also reflected by the Bland-Altman-Plot (Supplement Figure S2). Consequently, observing the PI difference over time, the application of Braunol has no relevant influence on the accuracy and reliability of the measurement.

Finally, we found that the comparison of the PI values between the fingers of different hands revealed an almost identical dynamic of both sides. With the use of a disinfectant, the PI values at the intervention finger still show the same dynamic behavior as the PI values on the reference finger. These results suggest that the perfusion index might be a reliable perfusion monitoring tool for replanted digits using it as a continuous comparison between the replant and the healthy equivalent. A significant increase of the difference between the values can indicate pathological perfusion events, for example due to vascular crises.

In order to investigate these considerations, a prospective study with replanted digits has already been started at the University Hospital of Regensburg.

Funding

None.

Ethical approval statement

This cross-sectional study was approved by the local ethics committee of the University Hospital Regensburg within the meaning of article 15 according to the Medical Association's professional code of conduct in Bavaria. (Application number: 19-1419-101, principal investigator: Dr. J. Hahn)

Volunteer consent

All participants received a participant's briefing and written informed consent was obtained from all subjects.

Declaration of Competing Interest

C.S and S.G. received technical devices from Masimo® for another study. The other authors declare no conflict of interest.

Acknowledgments

We would like to thank Mrs. Karolin Müller (center for clinical studies, University of Regensburg) for her support with the statistical analysis of the data.

Supplementary materials

Supplementary material associated with this article can be found, in the online version, at doi:10.1016/j.bjps.2022.02.031.

References

1. Breahna A, Siddiqui A, Fitzgerald O'Connor E, Iwuagwu FC. Replantation of digits: a review of predictive factors for survival. *J Hand Surg Eur* 2016;**41**(7):753–7. doi:10.1177/1753193415624663.
2. Kneser U, Horch R, Lehnhardt M. *Grundkurs Mikrochirurgie*. Berlin Heidelberg: Springer; 2016. doi:10.1007/978-3-662-48037-3.
3. Strauss C, Anker A, Klein S, et al. Monitoring free flaps and replanted digits via perfusion index - a proof of concept study. *Clin Hemorheol Microcirc* 2021 Oct 20 online ahead of print. doi:10.3233/CH-211295.
4. Hakverdioğlu Yönt G, Akin Korhan E, Dizer B. The effect of nail polish on pulse oximetry readings. *Intensive Crit Care Nurs* 2014;**30**(2):111–15. doi:10.1016/j.iccn.2013.08.003.
5. Tapar H, Karaman S, Dogru S, et al. The effect of patient positions on perfusion index. *BMC Anesthesiol* 2018;**18**(1):111. doi:10.1186/s12871-018-0571-z.

Katharina J. Fodor*, Alexandra Anker, Lukas Prantl, Talia Bosselmann, Sebastian Geis
University of Regensburg, Department of Plastic, Hand and reconstructive surgery, Franz-Josef-Strauss-Allee 11, 93053 Regensburg, Germany

Catharina Strauss
University of Augsburg, Department of Trauma, Orthopedic, Hand and plastic surgery, Stenglinstraße 2, 86156 Augsburg

*Corresponding author.
E-mail address:
Katharina-Jasmin.Fodor@stud.uni-regensburg.de (K.J. Fodor)

© 2022 British Association of Plastic, Reconstructive and Aesthetic Surgeons. Published by Elsevier Ltd. All rights reserved.

https://doi.org/10.1016/j.bjps.2022.02.031

Skin-sparing mastectomy and mastopexy: A safe "one step" option with immediate DIEP flap and simultaneous Nipple areola complex reconstruction

Dear Sir,

Background

The creation of the nipple-areola complex (NAC) is the final step in surgical restoration of the breast. It is often considered a secondary complement to the reconstruction and is usually performed after several months. This subjects the patient to a new surgical intervention and raises hospital costs, specially in the pandemic time with limited theater resource. [1-5]

Methods

We studied a prospective, longitudinal cohort, with patients diagnosed with breast cancer and severe ptosis or gigantomastia who underwent skin-sparing mastectomy with Wise pattern resulting in inverted T scar and resection of the nipple-areola complex to avoid necrosis of the NAC and reconstructed with an immediate deepitelized DIEP flap, performed in High Specialty Medical Unit No. 21, IMSS (Mexican Institute for Social Security). Monterrey NL. Mexico, from January 2018 to October 2020 (1 year 9 months).

The population was divided into two study groups:

Group A: patients with immediate reconstruction with DIEP flap and immediate NAC reconstruction.
Group B: Patients with immediate reconstruction with DIEP flap and delayed NAC reconstruction Figure 1.

Surgical technique

Mastectomy was carried out by the oncosurgery service, performing the Wise pattern for breast reduction. The abdominal flap is performed as previously described.[2]

A flap is placed in the receiving region and deepithelialized except for the area corresponding to the areola. Group A patients underwent immediate nipple reconstruction using the three-flap technique, two lateral and one central perpendicular flap that corresponds to the dome of the nipple. These are plane sutured with 5-0 nylon. For group B patients, only one circular area of skin was left from the flap corresponding to the areola. In both cases, this skin island was used to monitor the flap.

Group B patients underwent reconstruction of the nipple 6 months later.

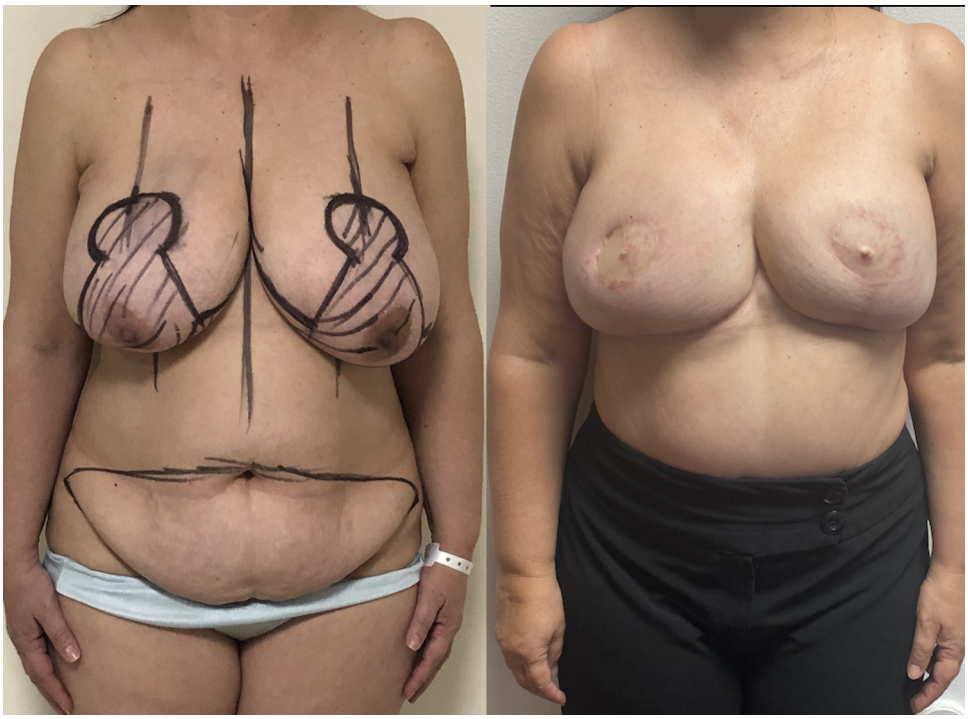

Figure 1 Bilateral mastectomy with breast reduction and immediate "one step" reconstruction with bilateral DIEP flap and bilateral NAC. Preoperative view marking and 5 months postoperative result.

Results

All patients underwent a skin-reducing mastectomy in a Wise-pattern with resection of the nipple areola complex and breast reconstruction with a microvascular deepitelized DIEP flap. All the patients had a nipple-to-sternal notch distance equal or grater than 25 cm.

From group A, 5 patients underwent bilateral skin reducing mastectomy in a Wise-pattern (10 reconstructed nipples) and 5 unilateral (5 reconstructed nipples) for a total of 15 immediate NAC reconstructions in a large ptotic breast.

In group B, 8 patients underwent bilateral skin reducing mastectomy in a Wise-pattern (16 reconstructed nipples) and 2 underwent unilateral mastectomy, for a total of 18 delayed NAC reconstructions in a large ptotic breast.

A total of 33 nipple-areola complex reconstructions were carried out, and were taken into account for the statistical analysis, from those.

From group A, 9 patients (93.4%, 14 NAC reconstructions) had a favorable evolution, while 1 patient (6.6%, 1 NAC reconstruction) presented necrosis of the nipple secondary to a partial fat necrosis underneath it. In group B (delayed reconstruction), all the reconstructed nipple-areola complexes evolved satisfactorily.

Using the statistical program SPSS 10.0 (Armonk, N.Y.), the incidence of NAC necrosis for immediate vs delayed reconstruction was compared using a Fisher's exact test, obtaining a $p = 0.455$.

Discussion

We performed nipple-areola complex reconstructions at the same surgical time as the DIEP flap breast reconstruction, performing the three-flap technique, two lateral and one central perpendicular flap, corresponding to the dome of the nipple.

The arguments to delay the reconstruction of the nipple-areola complex focus on the difficulty in determining the appropriate position of the nipple-areola complex, due to the scarring process and postoperative breast asymmetries. However, in experienced hands, positioning of the nipple-areola complex can be straightforward when performing a skin-sparing mastectomy using a Wise pattern design.

In our study, we found that the results, in terms of symmetry of the nipple-areola complex compared to the contralateral side, were aesthetically very satisfactory. The duration of surgery is not significantly longer when performing immediate nipple reconstruction.

Performing a breast reconstruction with immediate nipple-areola complex reconstruction has several advantages. The psychosocial issues that surround the patient with breast cancer that requires mastectomy can be anticipated, improving the aesthetics of the reconstruction, being performed faster and with fewer procedures and the great advantage of avoiding NAC necrosis by performing mastopexy-mastectomy at the same time.

Conclusions

Based on the results obtained in our research, we consider that performing immediate reconstruction of the nipple-areola complex simultaneously with a DIEP flap in large breast mastectomy in a Wise pattern is a feasible reconstructive option obtaining a "one step" total breast reconstruction, resulting in a positive psychological impact with lower costs for the patient, specially in the pandemic era.

Ethical Approval

The protocol was approved by the local Ethical Committee of the Mexican Institute of Social security, registration number: R-2021-1903-009.

Funding

None.

Conflict of Interest

None.

References

1. Escudero F. Historical evolution of breast reconstruction. *An Sist Sanit Navar* 2005;**28**(2):7–18.
2. Ph Blondeel, Hijjawi J, Depypere H, Roche N, Van Landuyt K. Shaping the breast in aesthetic and reconstructive breast surgery: an easy three- step principle. *Plast Reconstr Surg* 2009;**124**(2):372–82.
3. Healy C, Allen R. The evolution of perforator flap breast reconstruction: twenty years after the first DIEP flap. *J reconstr Microsurg* 2014;**30**:121–6.
4. Nahabedian M, Patel K. Autologous flap breast reconstruction: surgical algorithm and patient selection. *J Surg Oncol* 2016;**113**:865–74.
5. Lozken A, Dugal C, Desai K, McCullough M, Gruszynski M, Grant C. Time to completion of nipple reconstruction what factors are involved? *Ann Plast Surg* 2013;**70**(5):530–2.

De la Parra-Marquez Miguel
From the Division of Plastic and Reconstructive Surgery. Mexican Institute of Social Security (IMSS) No. 21 Pino Suárez y 15 de Mayo, col. Centro. c.p.64000. Monterrey Nuevo León, Mexico
Universidad de Monterrey. Av. *Ignacio Morones Prieto 4500 Pte. 6238. San Pedro garza García NL. Mexico*

Peña Victor
Universidad de Monterrey. Av. *Ignacio Morones Prieto 4500 Pte. 6238. San Pedro garza García NL. Mexico*

Torres-Roa Eduardo
From the Division of Plastic and Reconstructive Surgery. Mexican Institute of Social Security (IMSS) No. 21 Pino Suárez y 15 de Mayo, col. Centro. c.p.64000. Monterrey Nuevo León, Mexico

Charles-Lozoya Sergio
From the Division of Plastic and Reconstructive Surgery. Mexican Institute of Social Security (IMSS) No. 21 Pino Suárez y 15 de Mayo, col. Centro. c.p.64000. Monterrey Nuevo León, Mexico
Universidad de Monterrey. Av. *Ignacio Morones Prieto 4500 Pte. 6238. San Pedro garza García NL. Mexico*
E-mail address: drdelaparra@yahoo.com.mx (D.l.P.-M. Miguel)

© 2022 British Association of Plastic, Reconstructive and Aesthetic Surgeons. Published by Elsevier Ltd. All rights reserved.

https://doi.org/10.1016/j.bjps.2022.02.035

The process of autologous fat grafting in treating postmastectomy pain syndrome: What should we do?

Dear Sir,

Today, breast cancer surgical procedures are characterized by mastectomy with axillary dissection. Postmastectomy pain syndrome, one of the complications of mastectomy, presents chronic pain in the anterior side of the thorax, in the axilla, and/or in the upper half of the arm beginning after mastectomy and persists for more than 3 months after surgery. Autologous fat grafting has been shown to have significant beneficial effects on levels of pain and quality of life in patients who are suffering from postmastectomy pain syndrome.

In previous studies, Fabio et al.[1] and Marco et al.[2] reported that autologous fat grating relieves pain in patients with postoperative scarring and postmastectomy pain syndrome using the Coleman technique. However, the results from Martin et al.[3] study didn't present the same results as previous studies did.

Under scrutiny, first, the intervention group patients in Martin et al. study received fat injection using fat graft prepared by sedimentation and decantation. However, Fabio et al. and Marco et al. used centrifugation to prepare fat graft. Corrado et al.[4] indicate that although centrifugation could achieve higher fat purification efficacy when compared with sedimentation, sedimentation is able to provide less damaged adipocytes than standard centrifugation. Second, the standard aspiration 2-mm cannula, originally proposed by Coleman, was used in Martin et al. study. Whereas, Fabio et al. and Marco et al. used the 3.5-mm cannula to harvest fat. In the process of harvesting fat, the number of altered cells was statistically higher, when using a 3-mm cannula compared to 2-mm.[4] Ozsoy et al.[5] showed a higher number of viable adipocytes harvested with a 4-mm cannula as compared with 2-mm and 3-mm cannulas.

In conclusion, Fabio et al.[1] and Marco et al.[2] studies are characterized by higher fat purification efficacy but more damaged adipocytes and reported a significant result in treating postmastectomy pain syndrome when using autologous fat grafting; Martin et al.[3] study is characterized by lower fat purification efficacy but less damaged adipocytes and did not find a significant result in treating postmastectomy pain syndrome when using autologous fat grafting. The available data, however, are insufficient to ascertain whether we should guarantee the purification of fat or to ensure less damaged adipocytes when using autologous fat grafting to treat postmastectomy pain syndrome. There is no norm to point out which method of preparing fat graft can help patients who are undergoing postmastectomy pain syndrome achieve a better therapeutic effect to date. Further investigation will be needed in a future study.

Funding

None.

Ethical approval

None.

Declaration of Competing Interest

None.

References

1. Caviggioli F, et al. Autologous fat graft in postmastectomy pain syndrome. *Plast Reconstr Surg* 2011;**128**(2):349–52.
2. Klinger M, et al. Autologous fat graft in scar treatment. *J Craniofac Surg* 2013;**24**(5):1610–15.
3. Sollie M, et al. Autologous Fat Grafting as Treatment of Postmastectomy Pain Syndrome: a Randomized Controlled Trial. *Plast Reconstr Surg* 2022;**149**(2):295–305.
4. Rubino C, et al. A scanning electron microscope study and statistical analysis of adipocyte morphology in lipofilling: comparing the effects of harvesting and purification procedures with 2 different techniques. *Ann Plast Surg* 2015;**74**(6):718–21.
5. Ozsoy Z, Kul Z, Bilir A. The role of cannula diameter in improved adipocyte viability: a quantitative analysis. *Aesthet Surg J* 2006;**26**(3):287–9.

Li Minghao
The Second Clinical Medical School of Guangdong Medical University, Dongguan, Guangdong, China
E-mail address: liminghaodoctor@163.com (L. Minghao)

© 2022 British Association of Plastic, Reconstructive and Aesthetic Surgeons. Published by Elsevier Ltd. All rights reserved.

https://doi.org/10.1016/j.bjps.2022.02.075

Extensor indicis proprius transfer for the extensor pollicis longus tendon rupture with a two-incision technique

Dear Sir,

Spontaneous rupture of the extensor pollicis longus (EPL) tendon is a well-described complication of distal radius fractures but it is additionally attributed to other causes such as rheumatoid arthritis, tenosynovitis due to repetitive activity and systemic or local steroid injections.[1] The result of EPL tendon rupture is the patient's inability to extend the thumb and raise it to the level of the palm. Surgical treatment with tendon transfer is generally suggested and although many transfers have been described, tendon transfer using extensor indicis proprius (EIP) is the most popular as both tendons have similar amplitude and pulling direction.

The standard operative technique described by Schneider and Rosenstein in 1983 refers to three incisions; a transverse incision over the metacarpal neck of the index finger, a second transverse incision at the distal radius and a third curvilinear incision at the dorsum of the metacarpophalangeal joint of the thumb.[2] While this 3-incision technique with minor alterations has been used since 1983, we introduce a 2-incision technique, where an oblique incision in parallel with the route of EPL replaces the last two incisions of the standard technique and provides an adequate surgical exposure.

A 3 cm oblique incision (Figure 1) is made in parallel with the route of extensor pollicis longus (EPL) on the dorsal aspect of the hand. The distal end of the ruptured EPL is

Figure 1 The first 3 cm oblique incision in parallel with the route of EP, the distal end of the ruptured EPL is identified through the first oblique incision. The second 1,5 cm transverse incision just proximal to the index MP joint. EDC and EIP are identified through the second transverse incision with the EIP being ulnar and deep to the EDC. EIP is transected.

Figure 2 EIP is retrieved through the first incision. EIP is sutured to EPL with Pulvertaft technique using 3-0 nonabsorbable braided sutures in an over-tensioning technique (thumb in full extension - wrist in neutral position). [EPL: Extensor Pollicis Longus, EDC: Extensor Digitorum Communis, EIP: Extensor Indicis Proprius, MP: Metacarpophalangeal].

identified while the proximal end is noted to be retracted and the third compartment was empty in all patients. A second 1,5 cm transverse incision just proximal to the index metacarpophalangeal (MP) joint is made where the extensor digitorum communis (EDC) and extensor indicis proprius (EIP) tendons are identified with the EIP being ulnar and deep to the EDC. Excursions and independent function of the tendons are confirmed and the EIP is transected (Figure 1). The stump of EIP's distal end is sutured to the remaining communis tendon to the index finger in a side to side manner in order to maintain the centralization of the EDC. Through the first incision, the cutaneous branches of the radial nerve are recognized and protected, a tunnel is created in the subcutaneous tissue deep to the nerve branches and the transected EIP is identified. Then the EIP is retrieved (Figure 2), rerouted and sutured to the EPL tendon with Pulvertaft technique using 3-0 nonabsorbable braided suture material. The tendons are sutured while the thumb is in full extension and the wrist is in neutral position to minimize the possibility of restricted tendons' excursion due to the bulky weave. The possibility of tendon weave entrapment in extensor retinaculum is checked at that time and no complications were noted.

Postoperatively, the thumb is placed in a slightly extended position in a plaster splint extending to the tip of the thumb for three weeks that allowed free motion of the index finger. After three weeks, gentle range of motion exercise begins with intermittent splint protection and six weeks postoperatively, the splint is completely removed.

This technique has been applied to 18 consecutive patients aged ≥18 years old, between April 2017 and December 2019 in our Institution. Patients who had multiple ruptured tendons secondary to rheumatoid disease, operative fixation of a distal radius fracture, coexisting bone injury or soft tissue damage or other causes of impaired hand function before the diagnosis of EPL rupture were excluded from the study. At a mean follow-up of 16.5 months, all patients included in the study, showed good result with no complaint of pain, range of motion or any disability. No complications (e.g. rupture, infection) were noticed (supplementary material).

There are three surgical options for the treatment of EPL rupture: primary repair, tendon grafting and tendon transfer. Primary repair is possible only in relatively recent disruptions. Tendon grafting requires two tendon repair sites and has the difficulty of overcoming myostatic contracture for appropriate tensioning.[3] Tendon transfer using extensor indicis proprius (EIP) is the most popular as both tendons have similar amplitude and pulling direction.

The standard operative technique described by Schneider and Rosenstein in 1983 utilizes three incisions; a transverse incision over the metacarpal neck of the index finger, a second transverse incision at the distal radius and a third curvilinear incision at the dorsum of the metacarpophalangeal joint of the thumb.[2] This 3-incision technique with minor alterations has been used since the first description in 1983. Robert Strauch describes a similar 3-incision technique in Green's Operative Hand surgery, published in 2017.[4] According to our 2-incision technique, the oblique incision in parallel with the route of EPL provides the requisite exposure in order to identify the ruptured EPL stump as well as the proximally transected EIP. Then the EIP is pulled through the incision, transferred and sutured to the EPL tendon.

The EIP to EPL transfer is a reliable surgical treatment for EPL tendon rupture. The 2-incision technique we presented performed methodically provides a significant improvement of the patients' hand function with excellent objective results and high satisfactory rates.

Ethical approval

The institutional review board approved the human research protocol. The study's methodology adhered to the principles of the Declaration of Helsinki and all subjects provided their informed consent to participate in the study.

Funding

No financial support or benefits have been received by anyone of the authors.

Declaration of Competing Interest

None.

Supplementary materials

Supplementary material associated with this article can be found, in the online version, at doi:10.1016/j.bjps.2022.02.047.

References

1. Bjorkman A, Jorgsholm P. Rupture of the extensor pollicis longus tendon: A study of aetiological factors. *Scand J Plast Reconstr Surg Hand Surg* 2004;**38**(1):32-5.

2. Schneider LH, Rosenstein RG. Restoration of extensor pollicis longus function by tendon transfer. *Plast Reconstr Surg* Apr 1983;**71**(4):533–7.
3. Hamlin C, Littler JW. Restoration of the extensor pollicis longus tendon by an intercalated graft. *J Bone Joint Surg Am* 1977;**59**:412–14.
4. Green *Green's Operative Hand Surgery*. 7th Edition. Elsevier; 2017.

Konstantinos Ditsios, Charalampos Pavlopoulos, Panagiotis Konstantinou
2nd Orthopaedic Department Aristotle University of Thessaloniki, G. Gennimatas Hospital, Ethnikis Aminis 41, 54635, Thessaloniki, Greece

Athanasios Serlis
Resident in Orthopaedics, Trauma & Orthopaedic Department, Chelsea and Westminister Hospital, London SW10 9NH, United Kingdom

Triantafyllos Katsimentzas
2nd Orthopaedic Department Aristotle University of Thessaloniki, G. Gennimatas Hospital, Ethnikis Aminis 41, 54635, Thessaloniki, Greece

Iosafat Pinto
Orthopaedic Department, National Hospital of Veroia, Papagou, 59132, Veroia, Greece

Lazaros Kostretzis
2nd Orthopaedic Department Aristotle University of Thessaloniki, G. Gennimatas Hospital, Ethnikis Aminis 41, 54635, Thessaloniki, Greece

© 2022 British Association of Plastic, Reconstructive and Aesthetic Surgeons. Published by Elsevier Ltd. All rights reserved.

https://doi.org/10.1016/j.bjps.2022.02.047

Cosmetic procedure intention and normalization among young adults: Evidence (not) to worry?

Dear Sir,

As reported by the *American Academy of Facial Plastic and Reconstructive Surgery*, increasing numbers of young adults undergo cosmetic procedures.[1] In the Netherlands, young adults also constitute a growing proportion of injectable patients.[2] Nevertheless, little research has examined this increased popularity of cosmetic procedures among young adults. Thereto, we developed an online survey which explored young adults' intention to undergo cosmetic procedures and the perceived 'normality' of these procedures. Through a certified panel company, a total of 470 valid surveys with Dutch young adults aged 18–25 ($M_{age} = 21.00$, $SD_{age} = 2.26$; 56% female) were collected.

Young adults were asked to rate how likely they were to undergo particular procedures if they had unlimited funds and the procedure would be conducted by a trained expert (7-point scale: 1 = *No change under any circumstance*, 4 = *Maybe*, 7 = *Perform procedure*).[3] The mean likelihood of undergoing different cosmetic procedures was low; all means ranged from 1.70 for botulinum toxin to 3.40 for laser hair removal (see Table 1). Moreover, a vast majority of respondents (66.3%) indicated they would *never* undergo any of the procedures. We observed some variation between different procedures. Overall, respondents were more likely to consider non-invasive procedures, such as laser hair removal (36.10%) and other laser treatments (23.90%). Interestingly, injectables did not prove popular among our sample. Personal experience with procedures was minimal and ranged from just 1.1% of respondents (liposuction) to 6.2% (laser hair removal treatments).

Although few respondents indicated a personal interest in cosmetic procedures, they overestimated the number of people undergoing various procedures. For example, they estimated that nearly a third of Dutch adults opted for botulinum toxin and/or hyaluronic acid fillers, versus 3% in reality.[4] This overestimation may be linked to various normalizing influences such as (social) media and the role of vicarious experience.[5]

Conclusively, despite the overall rise in the number of young adults undergoing cosmetic procedures, the reported likelihood of undergoing cosmetic procedures remains low in our sample. Nevertheless, it will be valuable to track how normalization of cosmetic procedures will eventually result in greater cosmetic procedure acceptance and thereby likelihood of undergoing procedures.

Ethics

This research was approved by the Ethics Review Boards at the Erasmus University Rotterdam and the University of Amsterdam.

Declaration of Competing Interest

The authors declared no potential conflicts of interest with respect to the research, authorship, and publication of this article.

Funding

The authors received no financial support for the research, authorship, and publication of this article.

Table 1 Overview of results.

	Likelihood: mean	Likelihood:% no chance under any circumstance (score 1)	Likelihood:% likely to certainly willing to undergo procedure (scores 5-7)	Experience:% of respondents with experience with procedure	Normalization: Mean estimated% of population that did procedure
Botox	1.70 (1.47)	75.20%	7.40%	1.90%	30.90%
Liposuction	1.81 (1.64)	74.50%	9.80%	1.10%	24.20%
Fillers	1.86 (1.65)	72.20%	9.80%	2.60%	31.50%
Nose job	1.88 (1.68)	70.70%	9.40%	2.10%	23.60%
Hair transplant	1.94 (1.79)	72.70%	12.10%	2.10%	29.70%
Breast augmentation / breast reduction	2.00 (1.75)	69.00%	12.10%	1.50%	34.20%
Microdermabrasion	2.01 (1.72)	68.50%	12.30%	2.30%	22.80%
Chemical or fruit acid peeling	2.09 (1.80)	67.10%	14.50%	4.50%	24.80%
Laser treatment (other, such as treatments for wrinkles, age spots, scars, acne)	2.81 (2.16)	49.30%	23.90%	3.00%	34.30%
Laser treatment (hair removal)	3.40 (2.47)	43.90%	36.10%	6.20%	41.60%
Average	2.15	66.31%	14.74%	2.73%	29.76%

Note. **Likelihood** represents mean (with standard deviations between parentheses) likelihood (1 = *No change under any circumstance*, 4 = *Maybe*, 7 = *Perform procedure*). **Experience**: mean percentage of respondents that had procedures performed once or more often. **Normalization**: mean estimated percentage of Dutch population which respondents thought had undergone procedures (slider 0–100). Order of procedures from lowest mean likelihood to highest mean likelihood.

References

1. American Academy of Facial Plastic and Reconstructive Surgery. 2018 annual survey statistics. Available at https://www.aafprs.org/AAFPRS/News-Patient-Safety/Annual_Survey.aspx (last accessed 21 September 2021).
2. Zarringam D, Decates T, Slijper HP, Velthuis P. Increased usage of botulinum toxin and hyaluronic acid fillers in young adults. *J Eur Acad Dermatol Venereol* 2020;**34**(10):e602–4.
3. Swami V, Arteche A, Chamorro-Prezumic T, et al. Looking good: factors affecting the likelihood of having cosmetic surgery. *Eur J Plast Surg* 2008;**30**:211–18.
4. Decates T, De Wijs L, Nijsten T, Velthuis P. Numbers on injectable treatments in the Netherlands in 2016. *J Eur Acad Dermatol Venereol* 2018;**32**(8):e328–30.
5. Walker CE, Krumhuber EG, Dayan S, Furnham A. Effects of social media use on desire for cosmetic surgery among young women. *Curr Psychol* 2021;**40**(7):3355–64.

Anne-Mette Hermans
Erasmus University Rotterdam, Burgemeester Oudlaan 50, 3062 PA Rotterdam, the Netherlands

Sophie C. Boerman
University of Amsterdam, the Netherlands

Jolanda Veldhuis
Vrije Universiteit Amsterdam, the Netherlands

Tom Decates
Erasmus Medical Center, Rotterdam, the Netherlands
E-mail address: hermans@eshcc.eur.nl (A.-M. Hermans)

© 2022 British Association of Plastic, Reconstructive and Aesthetic Surgeons. Published by Elsevier Ltd. All rights reserved.

https://doi.org/10.1016/j.bjps.2022.02.069

Collaborating with medical illustrators to create optimal surgical figures for publications and beyond

Dear Sir,

"[Photography] shows form, structure, color and texture, all with complete realism. But it does not analyze, interpret or teach… It makes a dramatic picture, not a scientific one." - Max Brödel, JAMA 1941[1]

Those with medical training are familiar with the work of Dorothy Foster Chubb and Nancy Joy (known for Grant's Atlas of Anatomy), and more recently Frank Netter's illustrations and the art embedded in the UWorld question bank.[2-4] Medical illustrators are interdisciplinary professionals trained in translating complex scientific information into understandable, accessible, and memorable visuals. While they are historically associated with anatomical figures in textbooks, they may likely specialize in designing molecular imagery, three dimensional models, health apps, demonstrative evidence for legal cases, virtual reality media, and prosthetics.

Many medical illustrators have earned advanced degrees from programs within or affiliated with medical schools, which offer specialized training in medicine, media technology, and visual communication.[5] Regardless of the educational path taken, creating medical illustrations requires not only the technical skill to render a subject accurately, but the ability to distill the content into a story that will be understandable and accessible for the audience, omitting

superfluous detail and emphasizing only the content that reinforces the message. Many professionals choose to formalize their training through board certification, obtaining the designation Certified Medical Illustrator (CMI).[5] This process involves a written exam in drawing, medicine, and business policy, followed by a review of the professional portfolio.

The Association of Medical Illustrators estimates there are fewer than 2000 practicing medical illustrators in the world.[5] Some journals and academic institutions employ dedicated teams of medical illustrators and animators; many independent contractors make their portfolios available online. Illustrators may collaborate with a client to produce custom images, or they can license existing media from their archives. Medical illustrators typically do not sell their work but license it for specific uses (i.e., publication, presentation, or web). The geographic area, duration, and distribution format of an illustration will partly determine its cost, as will the style, complexity, deadline, and availability of existing research on the subject. It is therefore important to know the journal's copyright policies and technical requirements for figures at the outset of a project.

The teaching of surgical technique embodies unique challenges for which an accompanying figure can be indispensable. As a particularly artistically-inclined group, plastic surgeons often take on the time-intensive task of creating their own figures. While the surgeon is most familiar with the intricacies of the procedure, a medical illustrator can advise them on how best to present information in order to convey an idea. The work of Dr. Levant Efe[6], often published in the plastic surgery literature, exemplifies how an inventive angle, section, or cutout can amplify the message of a figure more successfully than would a direct, even photorealistic, rendering. Effective images increase the overall communicative value of publications describing surgical concepts. Collaboration with a professional medical illustrator can further elevate the quality of the figures and enhance the message of the research.

Funding

None.

Ethical approval

Not required.

Declaration of Competing Interest

None declared.

References

1. Brödel M. Medical illustration. *J Am Med Assoc* 1941;**117**(9):668-72.
2. Agur AM, Dalley AF. *Grant's atlas of anatomy*. 13th ed. Philadelphia, PA: Lippincott Williams and Wilkins; 2012.
3. Netter FH. *The netter collection of medical illustrations complete package*. 2nd ed. London, England: Elsevier Health Sciences; 2016.
4. UWorld, L. UWorld Medical. [cited 2022; Available from: https://medical.uworld.com/.
5. Learn About Medical Illustration. 2021; Available from: https://ami.org/medical-illustration/learn-about-medical-illustration.
6. Dr. Levent Efe, CMI (Accessed February 2022), 2022.

Julia L. Lerner
Mimi R. Borrelli
Loree K. Kalliainen
Division of Plastic and Reconstructive Surgery, Warren Alpert Medical School of Brown University, Brown University, Box G-9464, Providence, RI 02912, United States
E-mail address: julia_lerner@brown.edu (J.L. Lerner)

© 2022 British Association of Plastic, Reconstructive and Aesthetic Surgeons. Published by Elsevier Ltd. All rights reserved.

https://doi.org/10.1016/j.bjps.2022.02.079

"Pandemic puppies" - The UK animal bite pandemic

Dear Sir,

In the United Kingdom, animal bite injuries represent a substantial proportion of the acute plastic surgery workload. They also have a large economic impact, with dog bite hospital attendances and admissions estimated to have cost £71 million in 2017 alone.[1] During the COVID-19 pandemic there has been a widely publicised increase in animal ownership, with 3.2 million households in the UK acquiring a pet within a year of March 2019.[2] Animal charities such as The Kennel Club have expressed concerns that some of these pets have been acquired on impulse, without thought for the long-term commitment of ownership.[3] Since the relaxation of social distancing restrictions in early 2021, we have noted an apparent increase in the number of patients requiring treatment for animal bite injuries. The aim of this study was to evaluate the case load of animal bite injuries requiring emergency treatment, and to assess whether there has indeed been an increase in volume since the end of COVID-19 restrictions.

Method

Attendances to a tertiary centre emergency department were retrospectively reviewed from 1st April 2019 to 31st August 2021. Patients were identified through use of the term "animal bite" as the search parameter. Horse and insect-related injuries were excluded. To negate the effect of seasonal changes on case load volume, the time period of 1st April – 31st August was compared year-on-year, 2019 vs 2021. Data interpretation was performed using Microsoft Excel and GraphPad Prism. The paired *t*-test was used for statistical analysis.

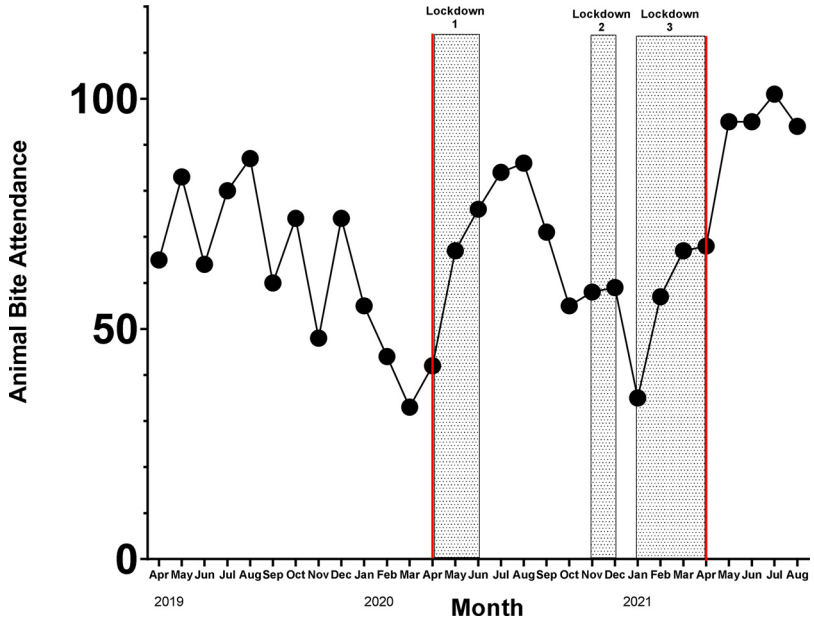

Figure 1 Animal Bite Emergency Department Attendance. Monthly attendance to a tertiary unit emergency department with animal bite injuries from April 2019 – August 2021. The time periods relating to the UK national lockdown have been highlighted.

Table 1 Study Group Demographics. The total number of attendances and referrals over the two time periods. There was no significant difference in average age or gender composition of the two groups.

	Pre-COVID-19 Restrictions April 1st – August 31st 2019	Post-COVID-19 Restrictions April 1st – August 31st 2021
Attendances with Animal Bite Injuries		
Number (n)	379	453
Sex		
Male, n (%)	170 (44.9)	204 (45.0)
Female, n (%)	209 (55.1)	249 (55.0)
Age		
Mean (range)	35.9 (0–87)	36.9 (0–97)
Plastic Surgery Referrals		
Number (n)	21	59

Results

A total of 1979 patients attended our emergency department with an animal bite injury over the 27-month period. In Figure 1, the trend of patient volume over time is demonstrated. There were 379 recorded attendances during April – August 2019; this rose to 453 during the same time period in 2021 *($p = 0.0426$)*. There was no significant difference in the average age or gender composition of the two cohorts (Table 1). The number of patients who were referred onwards from the emergency department to plastic surgery also significantly increased (21 vs 59, $p = 0.0012$).

Discussion

This is the first study examining the impact of the COVID-19 pandemic on the volume of animal bite injuries in the United Kingdom since the relaxation of social distancing restrictions in early 2021. We have demonstrated a 19.5% increase in the number of emergency department attendances and a 180% increase in onward referrals to plastic surgery. This is likely to result in an increased workload for plastic surgery units and may impact on future workforce planning.

The reasons underlying this increase are likely multifactorial. A proportion can be attributed to the large rise in pet ownership during the pandemic. We also hypothesise that some pets acquired during the pandemic may be inadequately socialised and poorly trained due to the social distancing restrictions - and this may result in greater aggression and likelihood of biting. Furthermore, it is possible that pets acquired prior to the pandemic may have undergone behavioural changes secondary to altered home routines and reduced socialisation with other humans and animals. Our study design eliminates seasonal trends as a confounding factor. Previous work by *Tulloch* et al. reviewed emergency department attendances from dog bite injuries in a paediatric population from July 2016 – September 2020. They found that attendance increased during periods of lockdown; this is in contrast to our findings, where lockdown does not appear to have had a major impact on attendance.[4]

Our study is limited by its single centre and retrospective design. It is not clear whether our findings are representative of the national picture, and a UK-wide analysis is required. Nevertheless, we believe this study gives important findings that are of relevance for plastic surgery services in the UK and the wider community.

Funding

The author(s) received no financial support for the research, authorship, and/or publication of this article.

Ethical approval

Not required

Declaration of Competing Interests

The author(s) declare no potential conflicts of interest with respect to the research, authorship, and/or publication of this article.

References

1. Tulloch JSP, Owczarczak-Garstecka SC, Fleming KM, et al. English hospital episode data analysis (1998–2018) reveal that the rise in dog bite hospital admissions is driven by adult cases. *Sci Reports* 2021;**11**:1–12 2021 111. doi:10.1038/s41598-021-81527-7.
2. Households "buy 3.2 million pets in lockdown" - BBC News. https://www.bbc.co.uk/news/business-56362987. Accessed 24 Oct 2021
3. 1 in 4 admit impulse buying a pandemic puppy | Kennel Club. https://www.thekennelclub.org.uk/media-centre/2020/august/the-covid-19-puppy-boom-one-in-four-admit-impulse-buying-a-pandemic-puppy/. Accessed 24 Oct 2021
4. JSP T, S M, V P, et al. Paediatric emergency department dog bite attendance during the COVID-19 pandemic: an audit at a tertiary children's hospital. *BMJ Paediatr open* 2021;**5**. doi:10.1136/BMJPO-2021-001040.

Oliver Jones
Alexander Freethy
Christine Quinlan
Department of Plastic Surgery, John Radcliffe Hospital - West Wing, Headley Way OX3 9DU, Headington
E-mail address: oliverj@doctors.org.uk (O. Jones)

© 2022 British Association of Plastic, Reconstructive and Aesthetic Surgeons. Published by Elsevier Ltd. All rights reserved.

https://doi.org/10.1016/j.bjps.2022.02.064